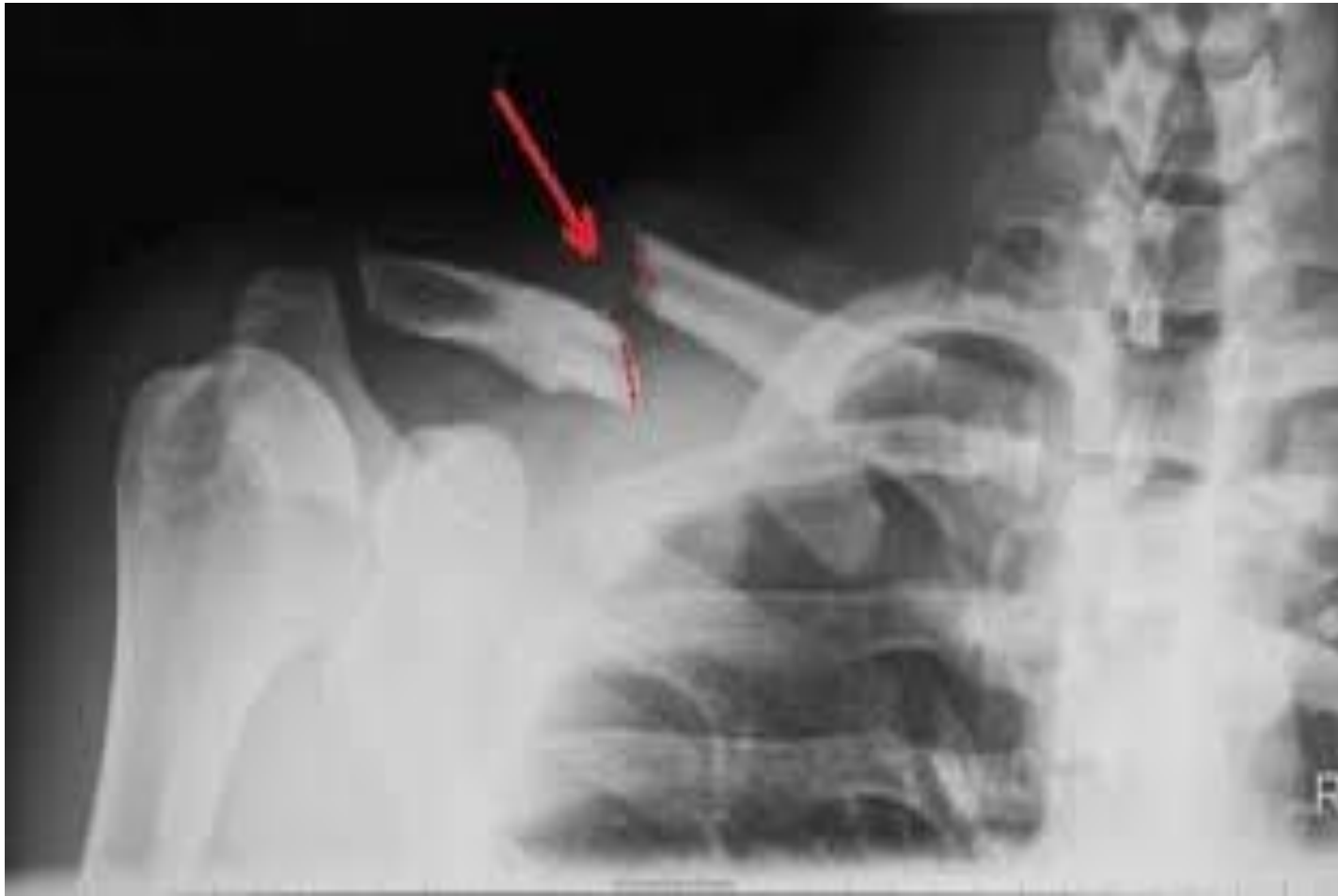
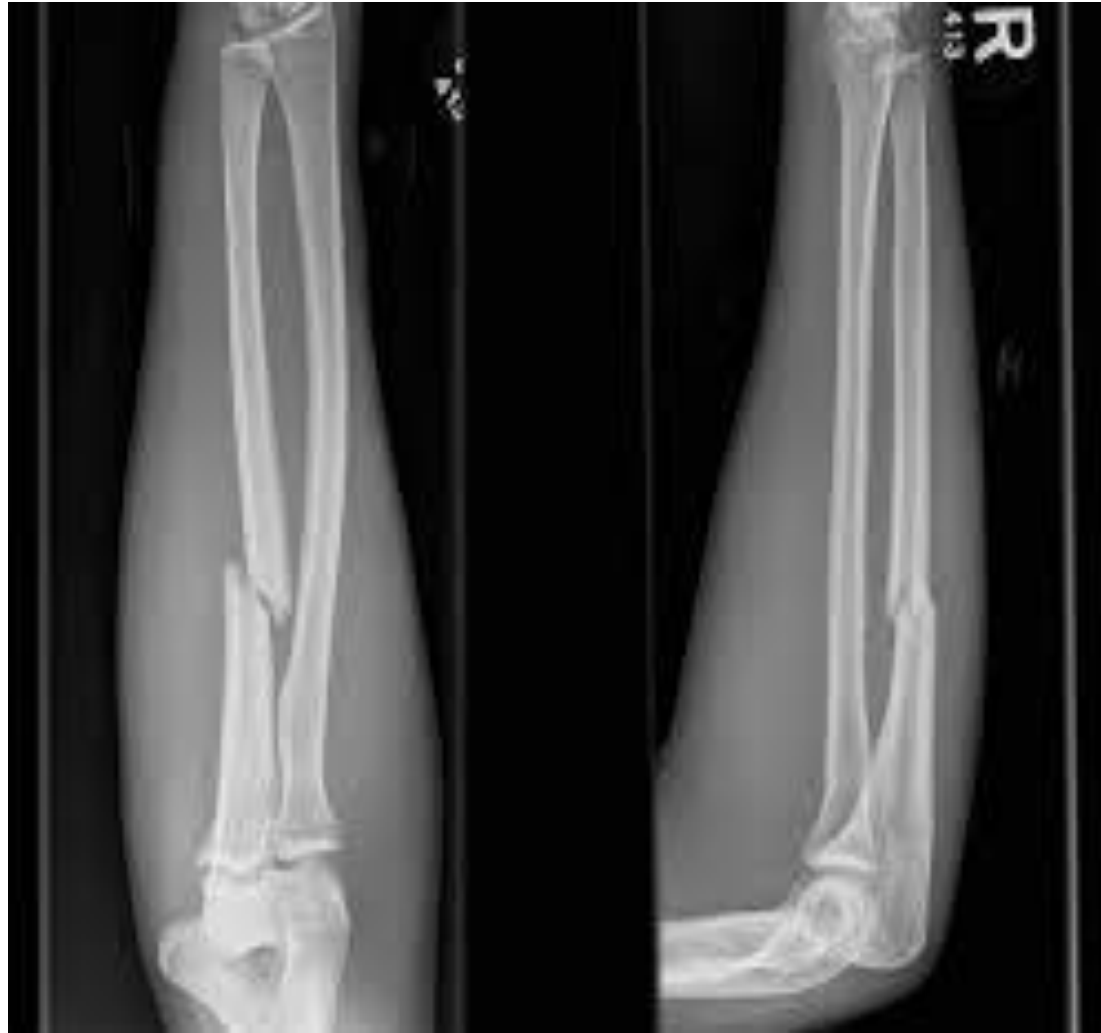
RADIOLOGICAL STUDIES

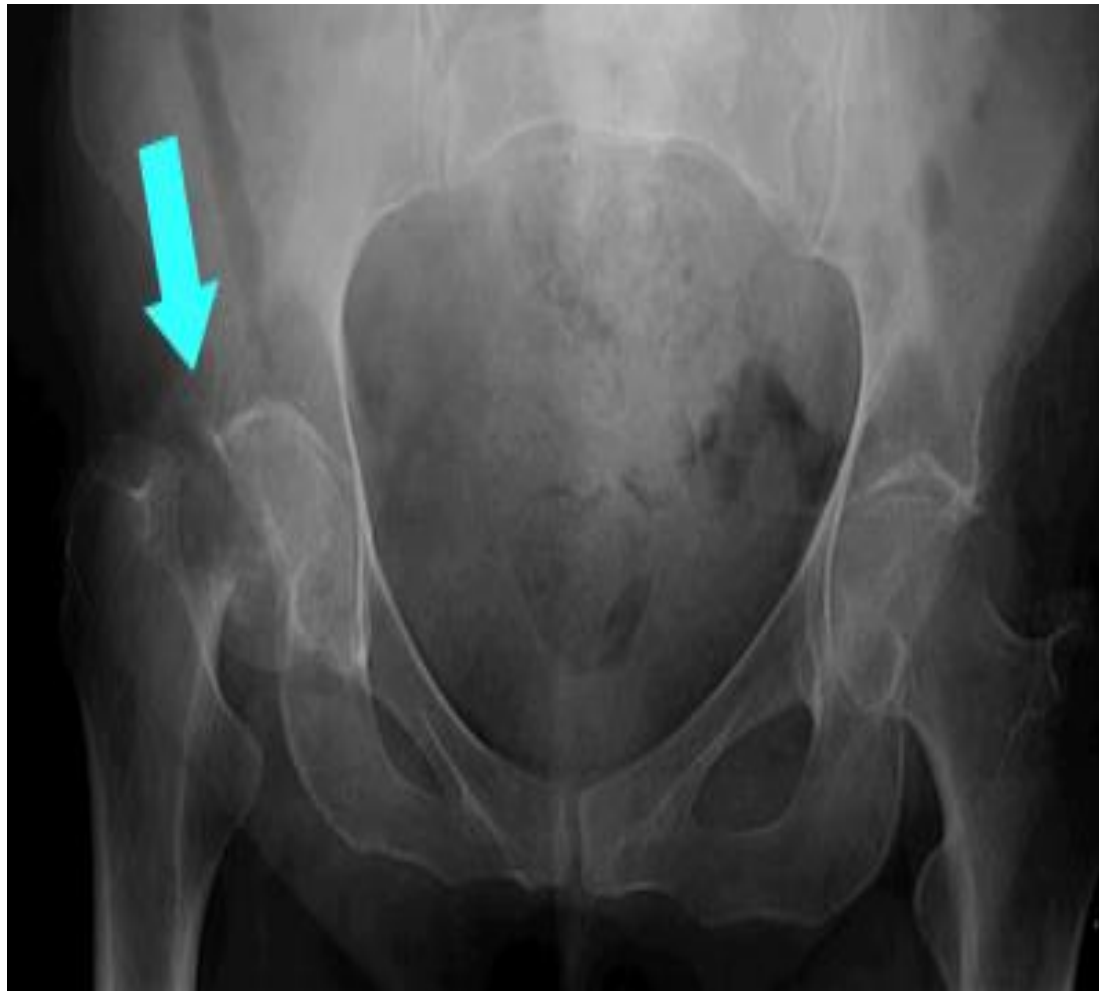
CLAVICLE FRACTURE

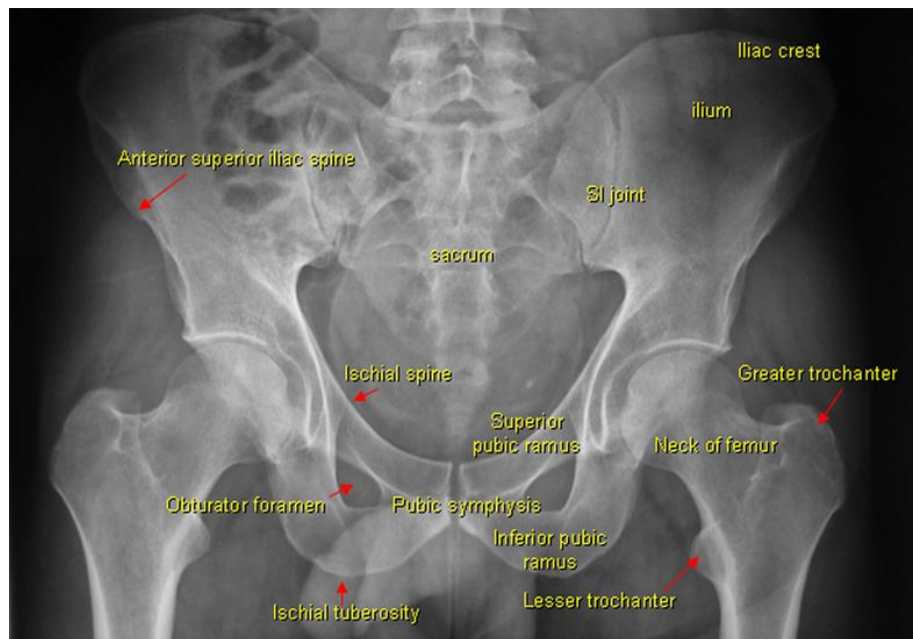
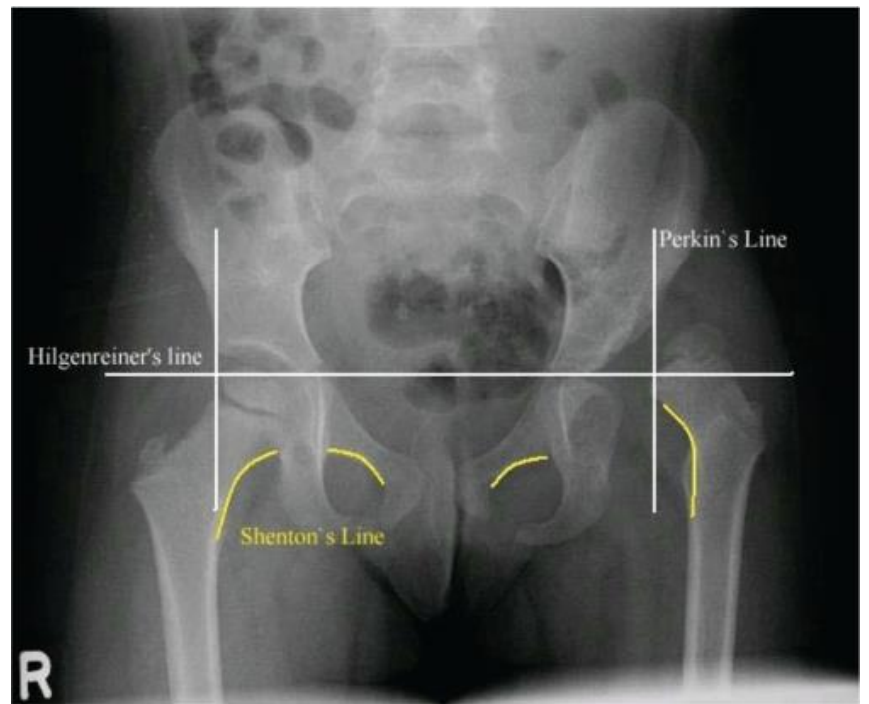
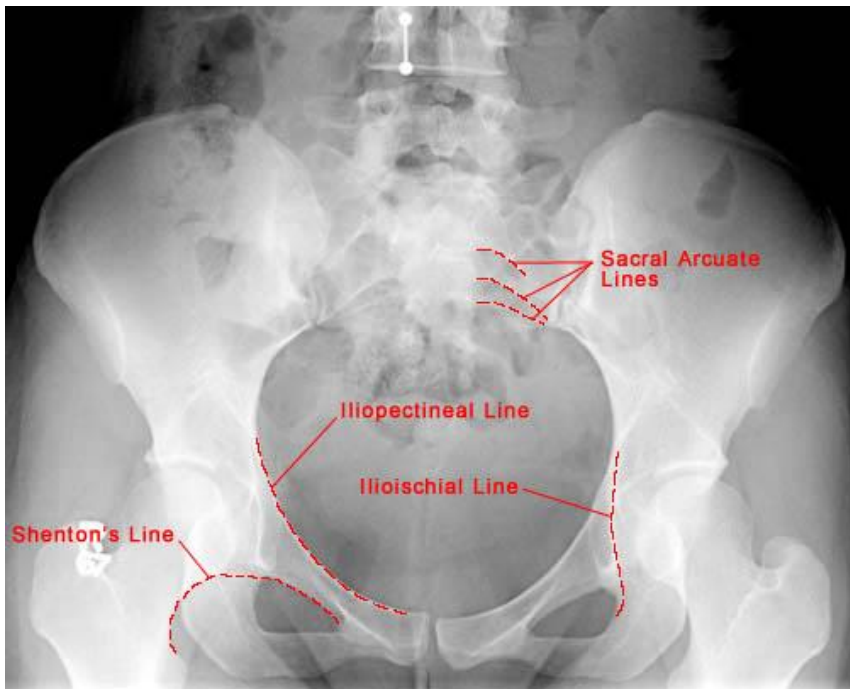


RIGHT RADIUS ULNA FRACTURE

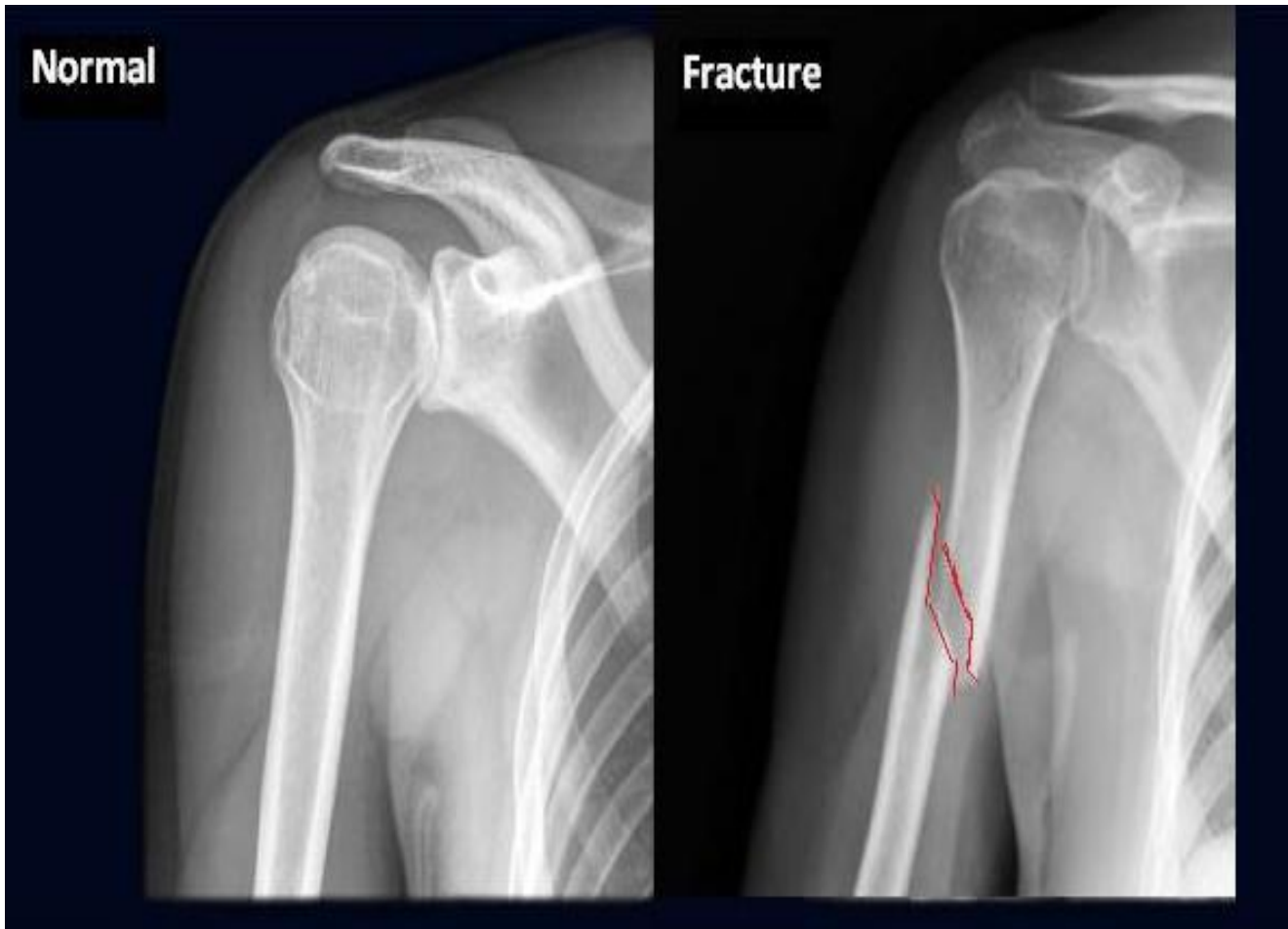


RIGHT FEMUR NECK FRACTURE

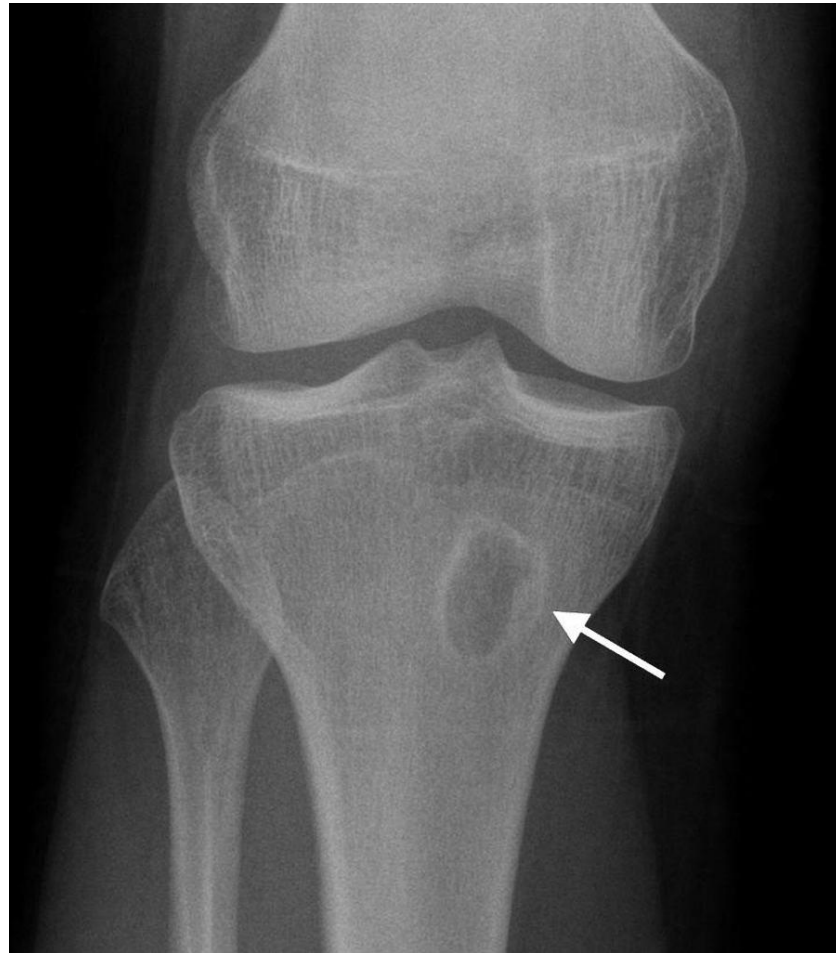




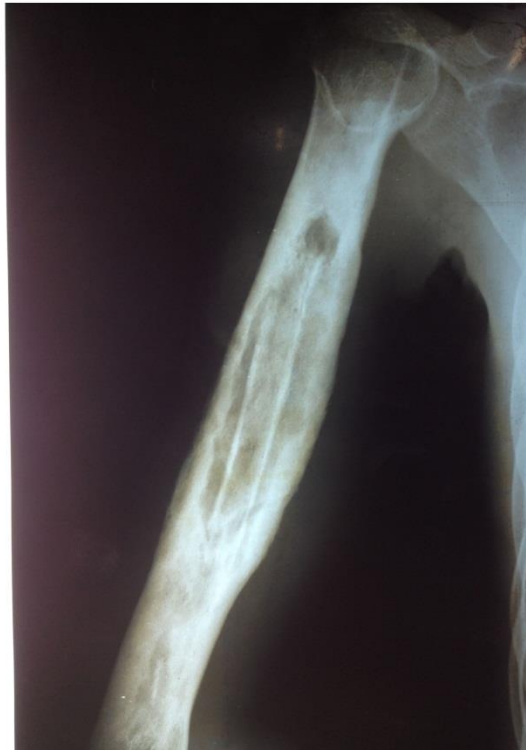HUMERUS FRACTURE



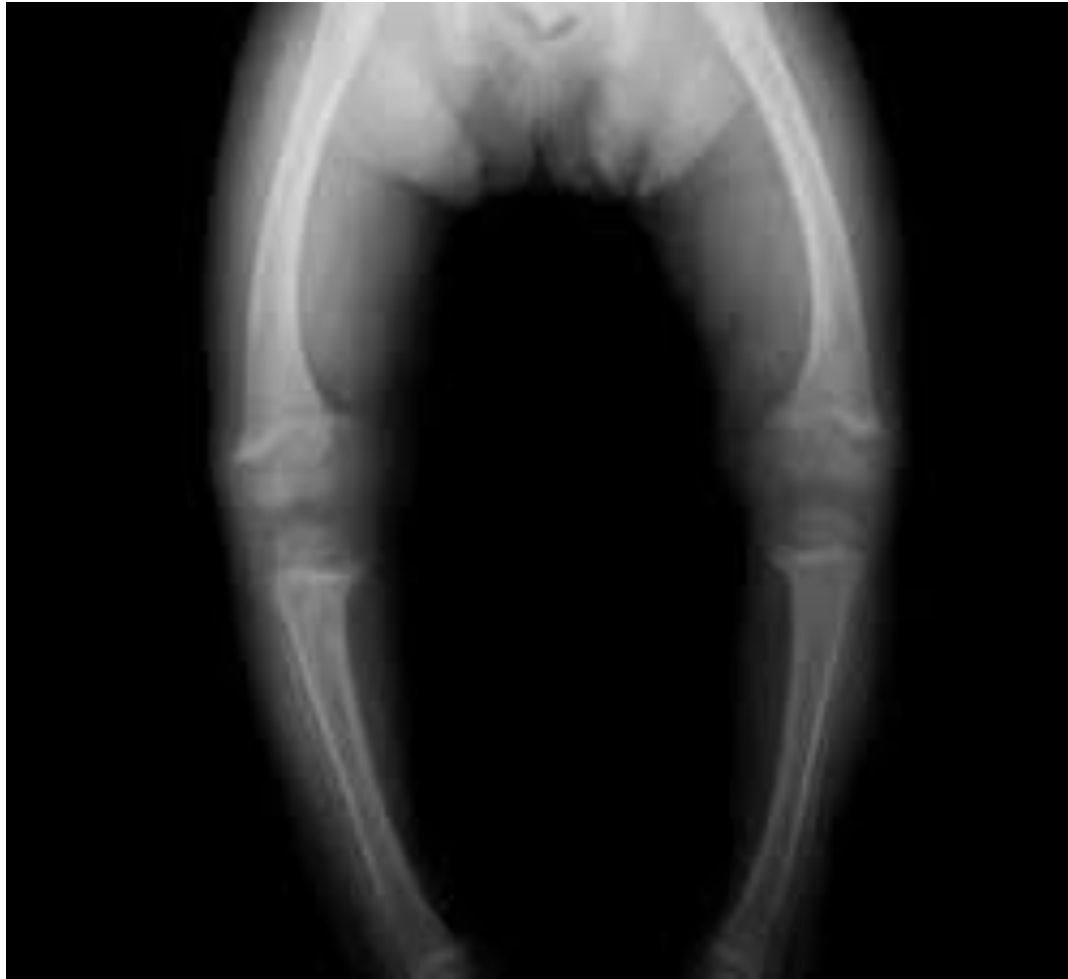BRODIES ABSCESS



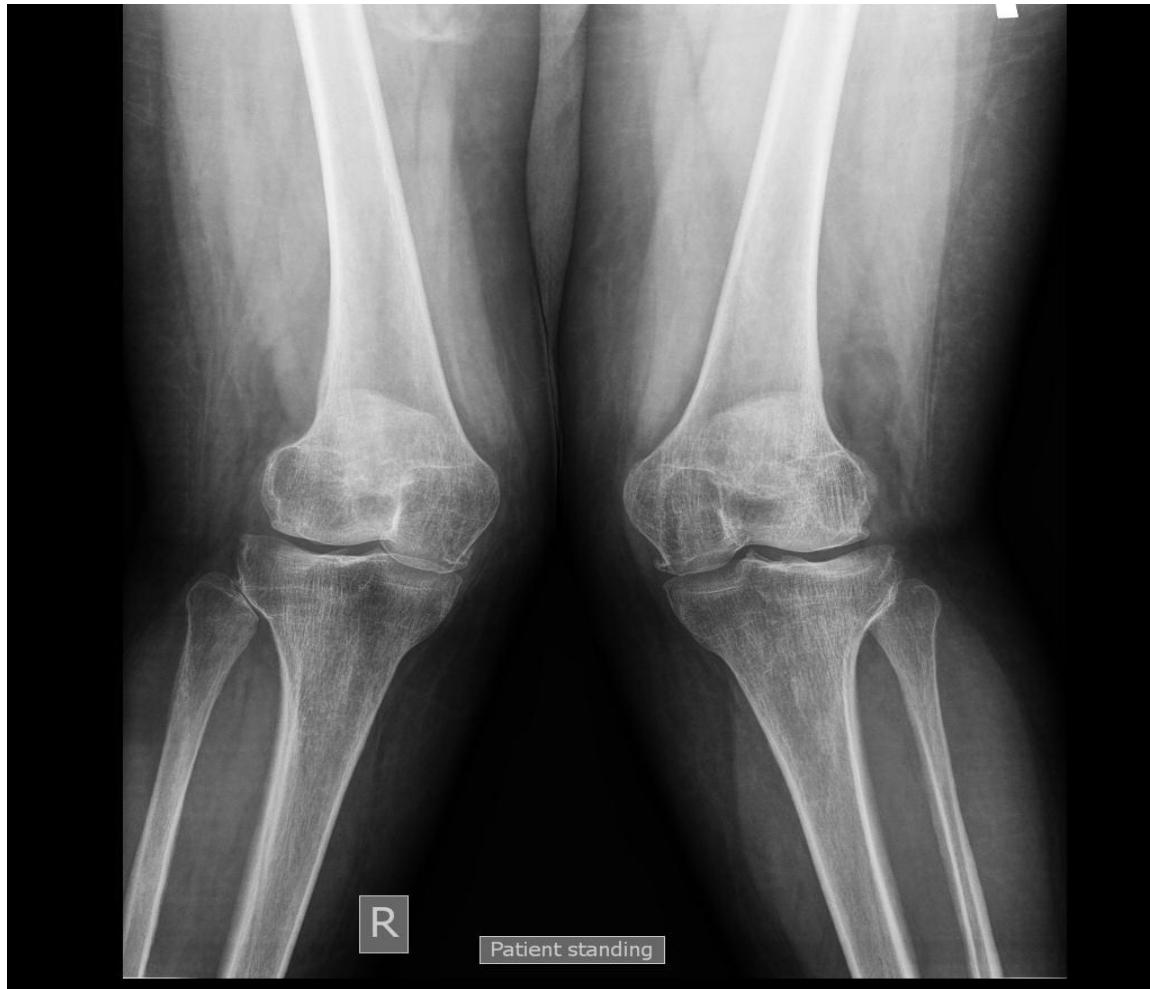CHRONIC OSTEOMYELITIS OF HUMERUS



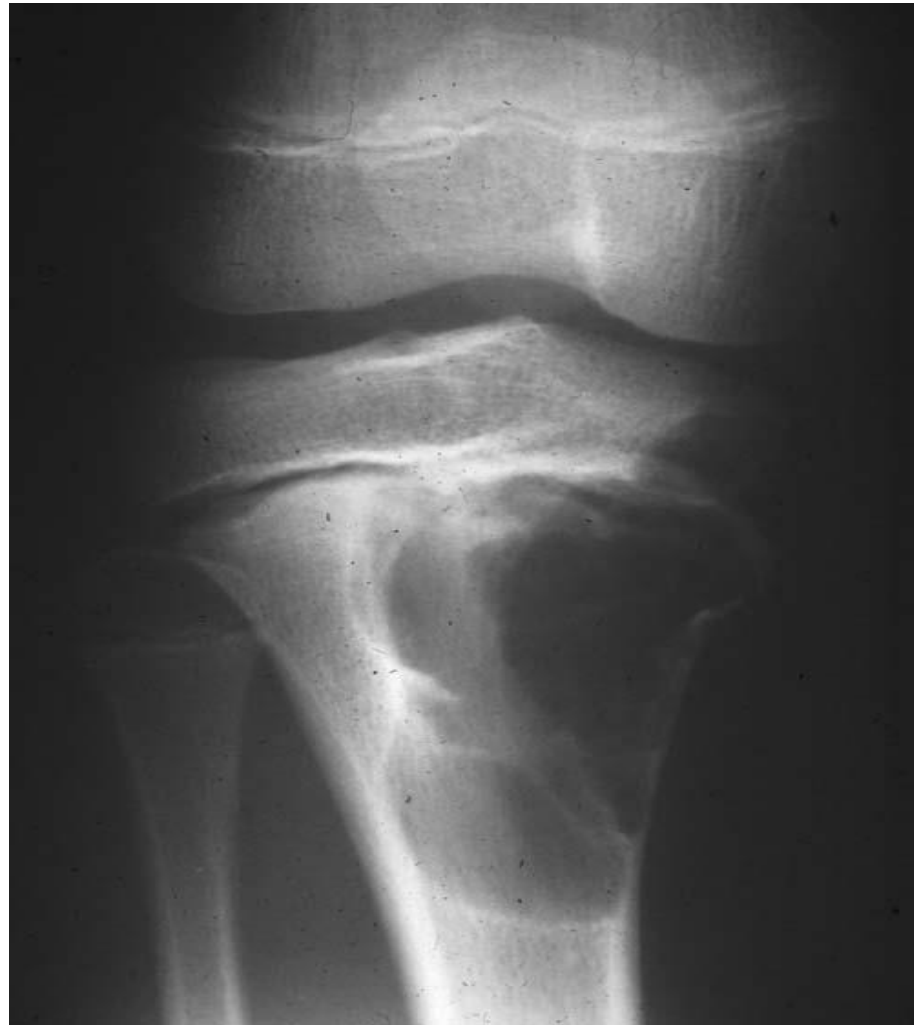BOW LEGS



KNOCK KNEES



SIMPLE BONE CYST



B/L OA KNEE

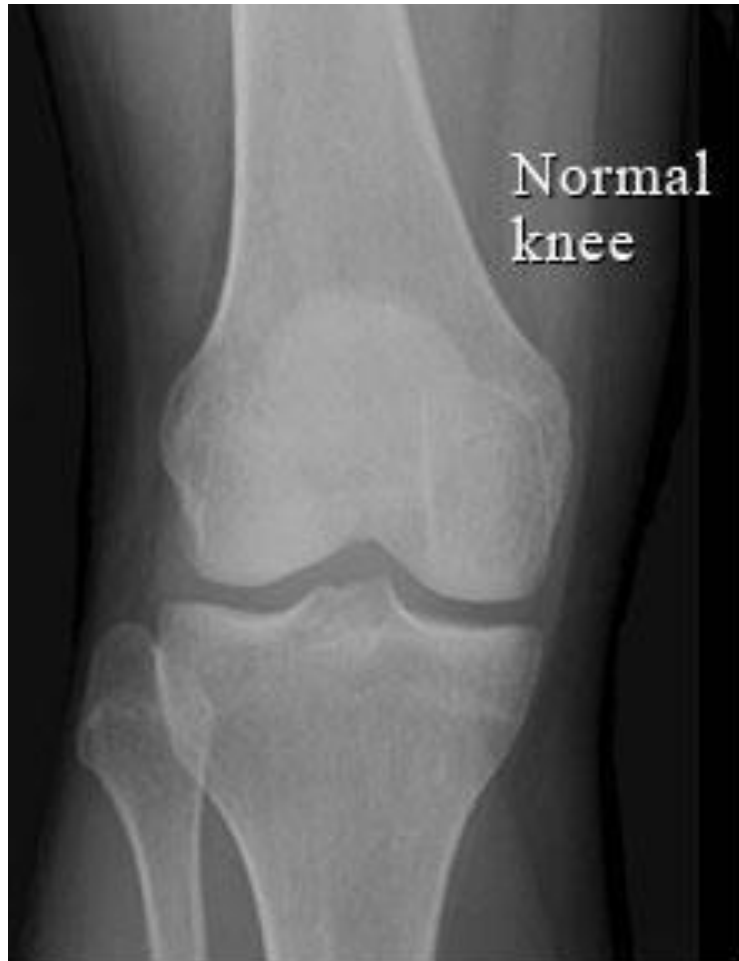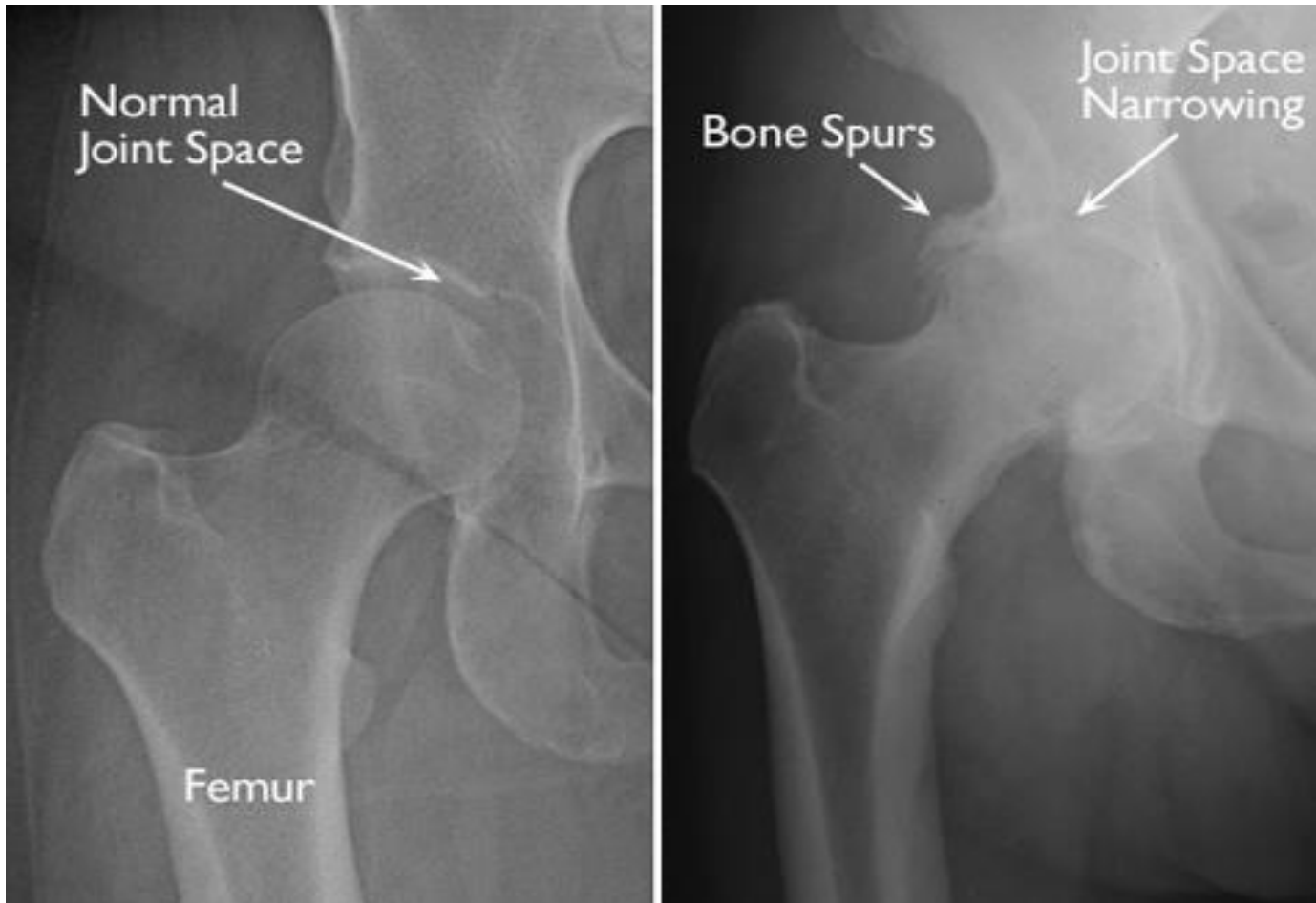


Figure 1

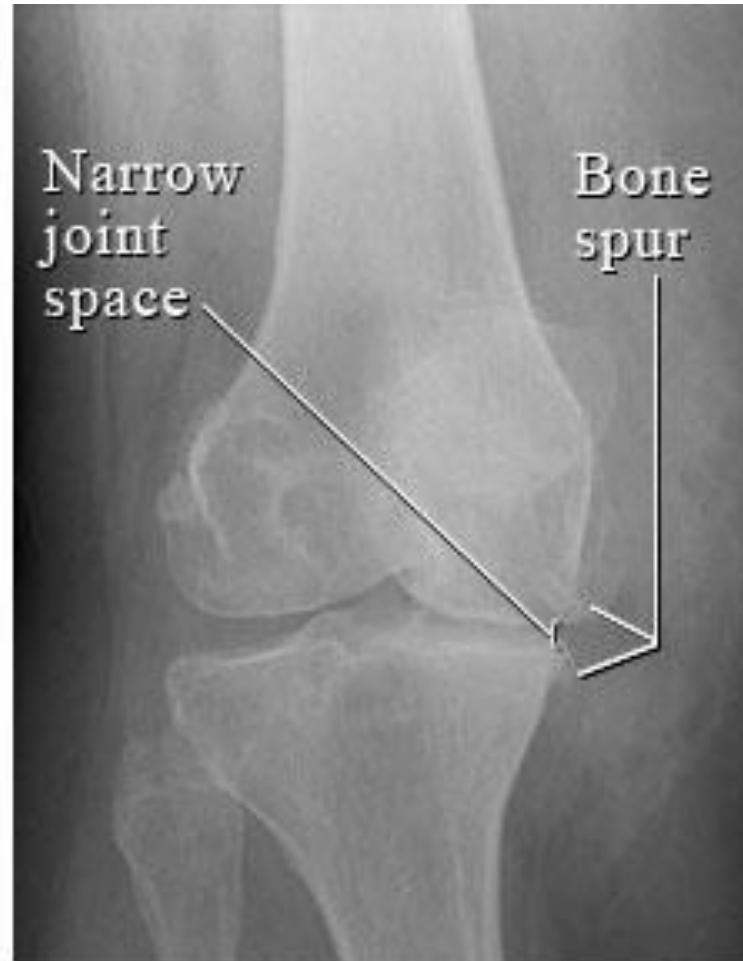

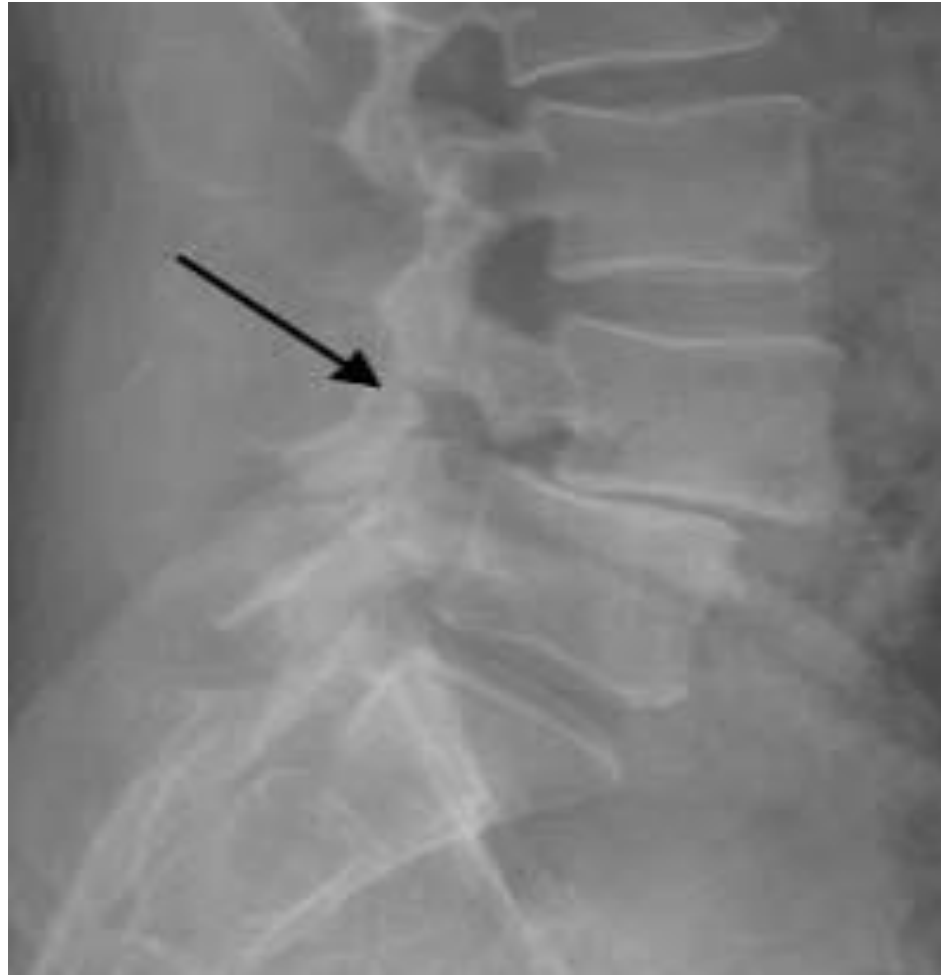Figure 2

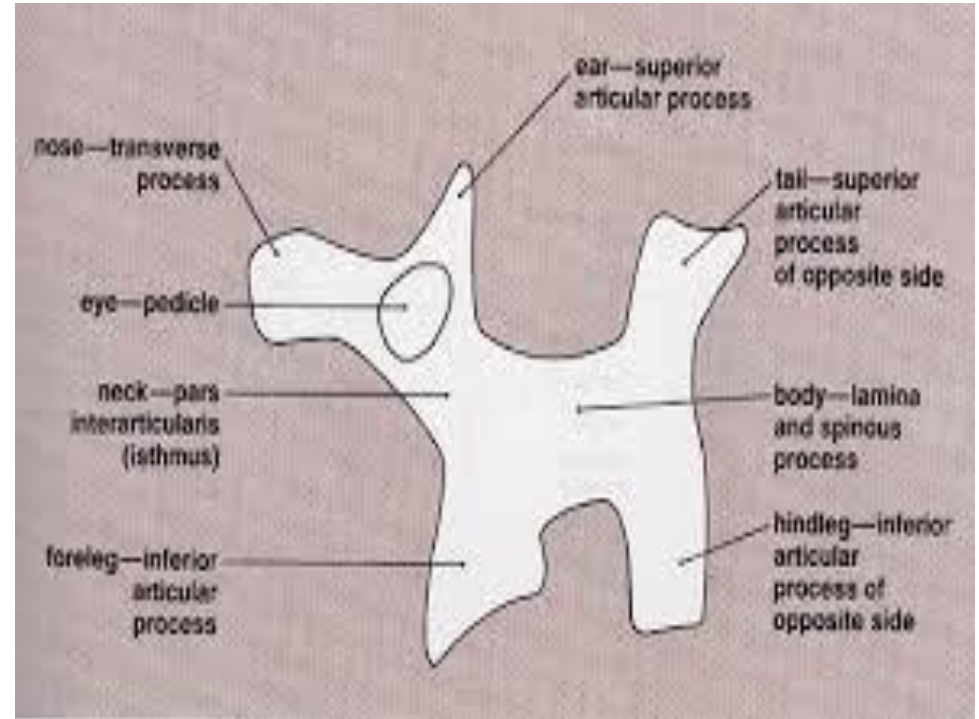
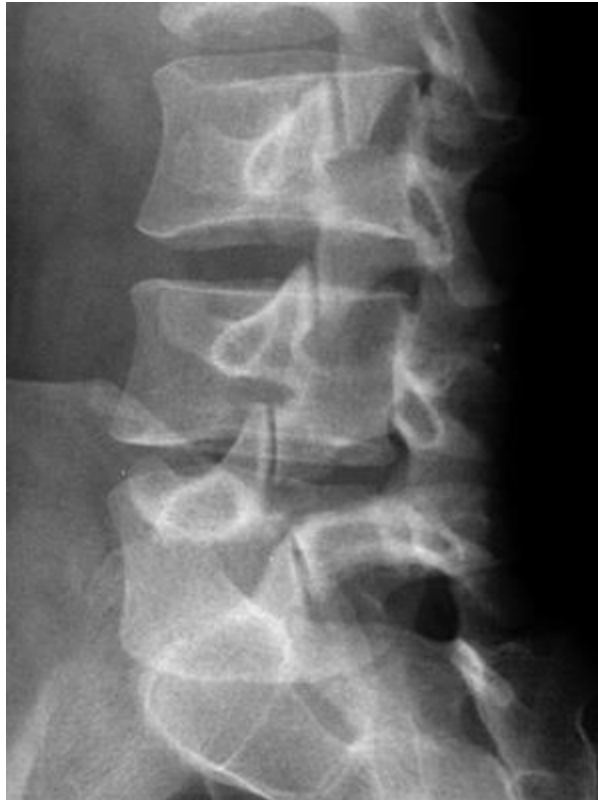RIGHT OA HIP



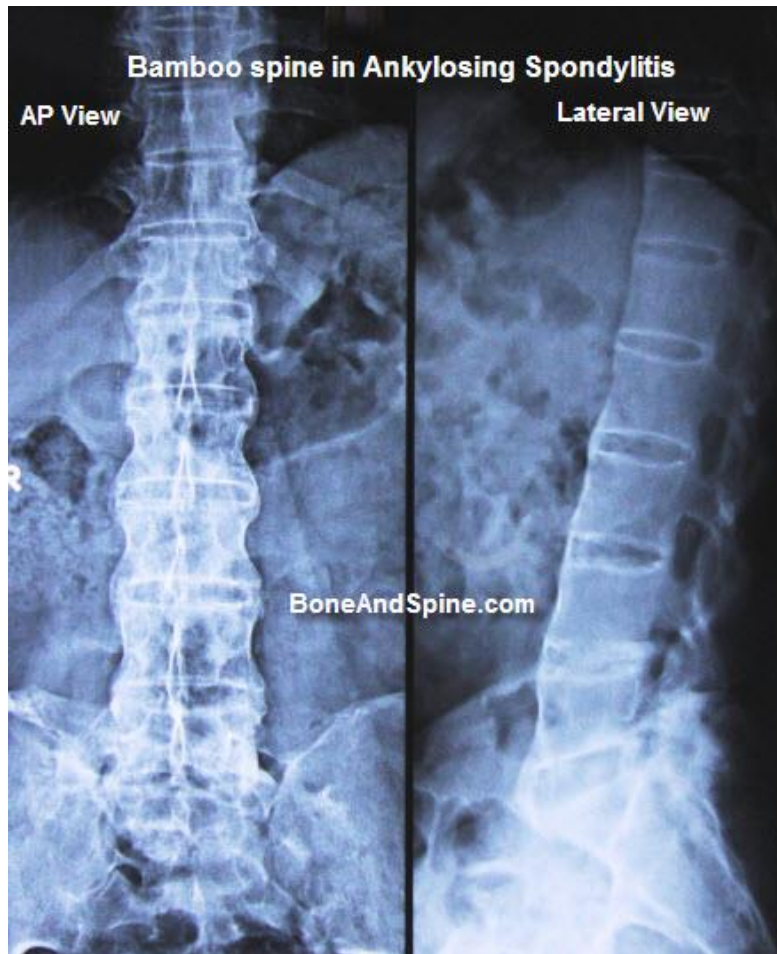
SPONDYLOLISTHESIS



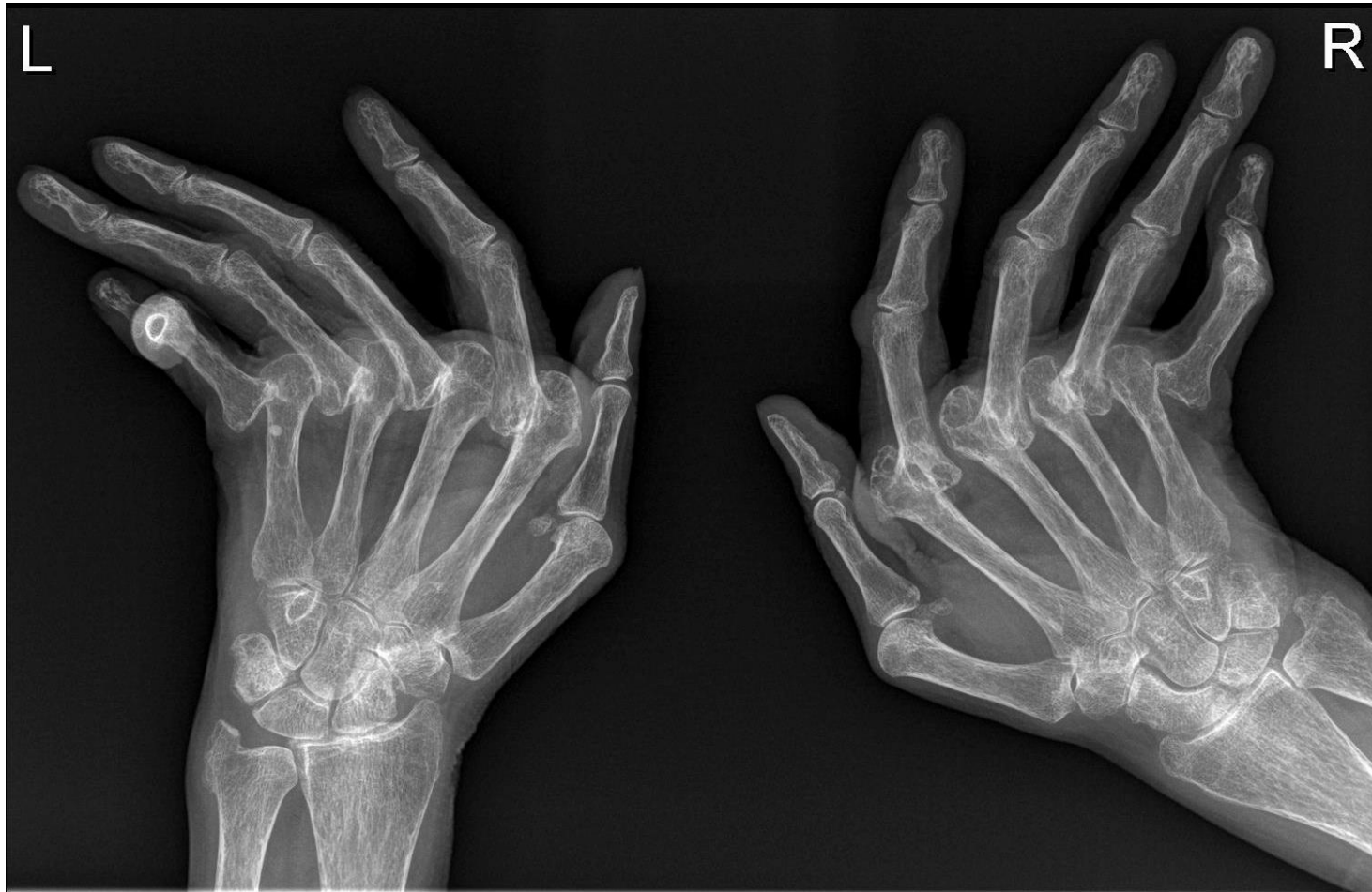SCOTTY DOG SIGN



BAMBOO SPINE

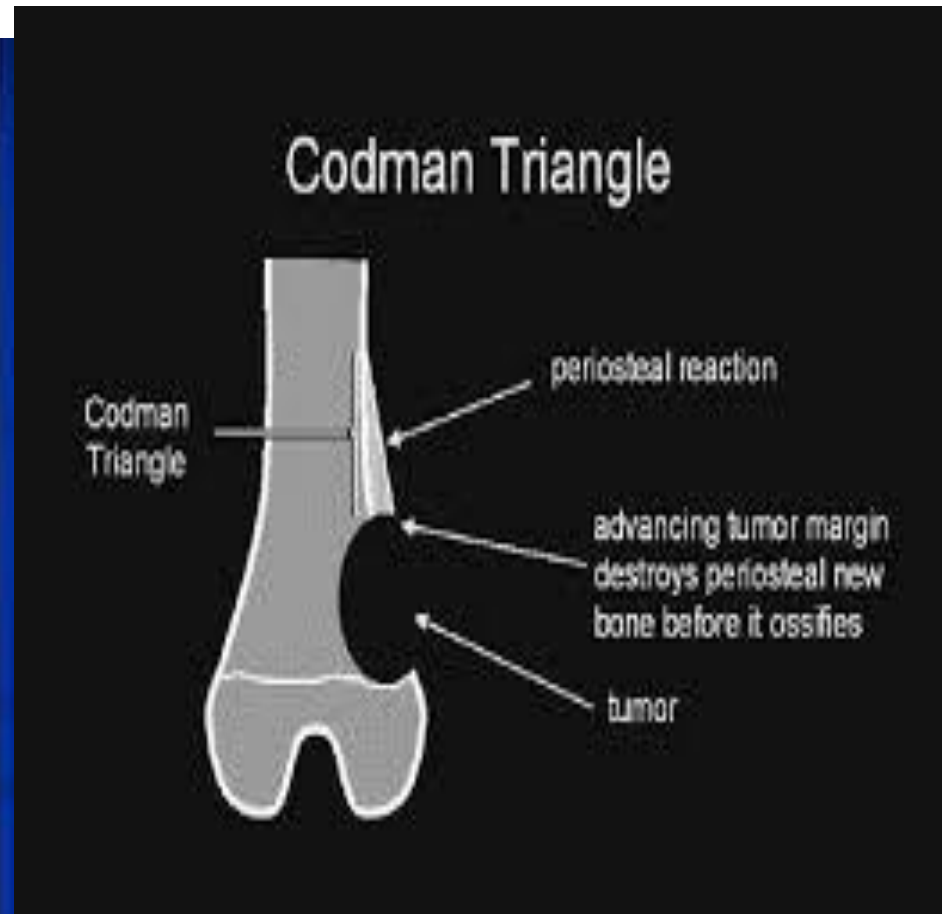
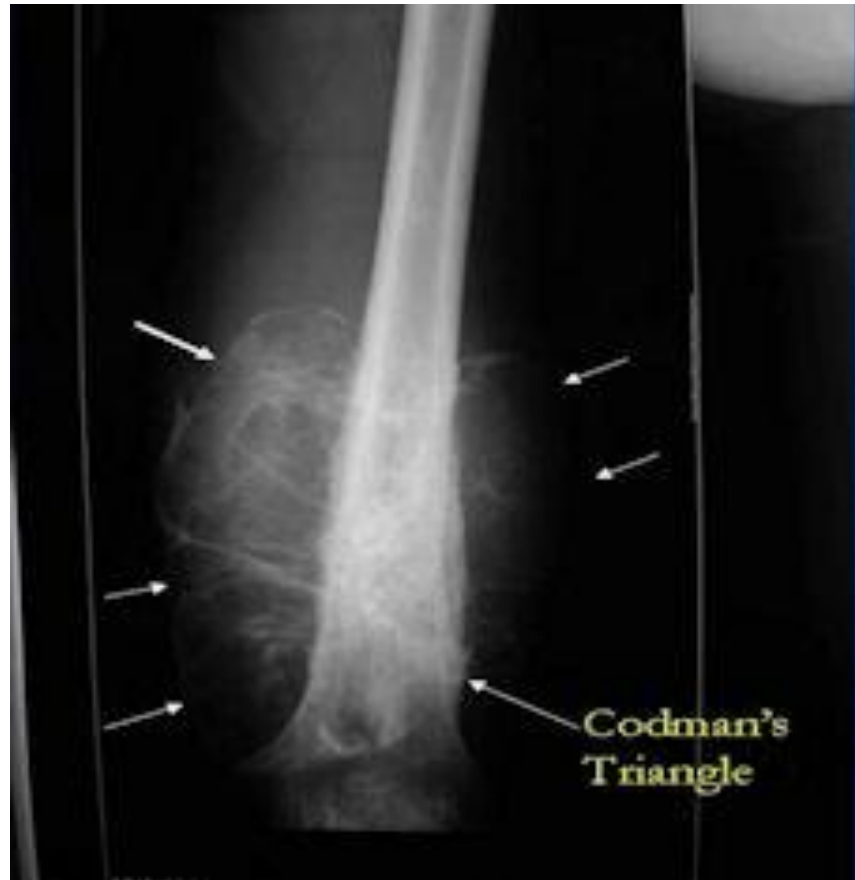

RHEUMATOID ARTHRITIS



WIND SWEEPING DEFORMITY

OSTEOSARCOMA



EWINGS SARCOMA

